

Bronchial artery embolization: experience with 10 cases

Bahri Üstünsöz, Uğur Bozlar, Fatih Örs, Sedat Gürkök, Arzu Balkan, Turan Ilıca

PURPOSE

To report our experience with 10 cases of bronchial artery embolization (BAE).

MATERIALS AND METHODS

The study included 18 cases (11 men and 7 women between 21 and 81 years of age, average 52 years), whose massive hemoptyses could not be controlled with conservative and bronchoscopic methods and were sent to the digital subtraction angiography unit between August 2002 and May 2004. Of these 18 cases, BAE was performed in 10 (7 men and 3 women between 21 and 78 years of age, average 54.2 years). An aortogram with a 5F pigtail catheter and a selective bronchial angiogram with a 4F glide Cobra (C2) catheter was obtained in every case. The same C2 catheters that had been used for bronchial angiography were also used for BAE in 7 cases. Hydrophilic microcatheters were additionally needed for BAE in the other 3 cases. Particles >250 microns (polyvinyl alcohol [PVA], Embosphere® microspheres), mechanical coils, or a combination of both were used for BAE.

RESULTS

The etiologies of 10 cases in which BAE was performed were tuberculosis (n=3), sarcoidosis (n=3), bronchiectasis (n=2), and malignancy (n=2). Arterial bronchial pathology was also seen in the non-selective angiographic studies of 4 of the 10 BAE cases. Hemoptysis was controlled in all BAE cases in the first session. Recurrences were observed in 2 cases that were embolized with only mechanical coils during the first month follow-up and hemoptysis was again controlled with microparticle embolization with Embosphere® microspheres. All 10 cases were followed-up for 1-21 months (average, 8 months).

CONCLUSION

Non-selective angiographic examination alone, is not sufficient enough to detect the vascular pathology causing a massive hemoptysis. A selective study must be performed in every case. The cost of angiography can be lowered by using the same 4F glide C2 catheter for BAE. It may not be safe to use only mechanical coils in BAE cases. There is a need for studying additional cases to have more definitive conclusions.

Key words: • hemoptysis • bronchial artery • therapeutic embolization

From the Departments of Radiology (B.Ü. ✉ bustunsoz2000@yahoo.com, U.B., F.Ö., T.I.), Thoracic Surgery (S.G.), and Thoracic Diseases (A.B.), Gülhane Military Academy of Medicine, Ankara, Turkey.

Received 7 June 2004; revision requested 19 September 2004; revision received 22 September 2004; accepted 3 October 2004.

Massive hemoptysis is defined as the expectoration of 300-600 ml of blood in 24 hours, although the quantity shows variation (1). It has been reported that 28% of all clinicians working in thoracic clinics will encounter mortality secondary to hemoptysis annually (2). Death, in most cases, is secondary to asphyxiation due to aspiration more so than bleeding. Bronchial artery embolization (BAE) for the treatment of hemoptysis was first described in 1973 (3-5). Additional studies emphasizing the safety and efficacy of BAE followed this study (6-8). Herein, we report our experience with BAE in 10 cases with massive hemoptysis.

Materials and methods

In August 2002, the radiology, chest diseases and chest surgery clinics of our hospital developed a common algorithm in the evaluation and treatment of cases with massive hemoptysis. According to this, if cases involving a massive hemoptysis were clinically and hemodynamically stable, they were evaluated with chest radiography; if a chest radiogram was not helpful in determining the etiology and localization, patients were then evaluated with computed tomography (CT). After this stage, patients underwent diagnostic bronchoscopy followed by therapeutic bronchoscopy.

Sixteen cases whose hemoptyses could not be controlled following these procedures were taken to the angiography unit. Unstable cases with massive hemoptysis immediately underwent bronchoscopic procedures following appropriate supportive treatment. Two cases in which hemoptysis could not be controlled with this approach were intubated and brought to the digital subtraction angiography (DSA) unit. Diagnostic angiography was performed with this algorithm in 11 male and 7 female patients (age range, 21-81 years; average age, 52 years) between August 2002 and May 2004.

Initially, non-selective aortograms were obtained with 5F pigtail catheters (Cook, Bjaeverskov, Denmark). Following this, selective bronchial arteriograms were obtained with 4F glide catheters (Terumo Europe NV, Leuven, Belgium). If these studies were negative, non-bronchial systemic arteries such as the intercostal and subclavian arteries were evaluated with selective 4F glide catheterization. Bronchial artery embolization was not performed in 8 cases because contrast material extravasation, vascular enhancement, or pooling that indicated chronic inflammation were not detected in bronchial or non-bronchial systemic arterial studies. These 8 cases were treated with clinical follow-up and palliative approach. Hemoptyses of these patients were controlled in an average of 36 hours (range, 1-51 hours).

Bronchial artery embolization was performed in the other 10 cases. The same 4F glide catheters (C2) that were used for bronchial angiography

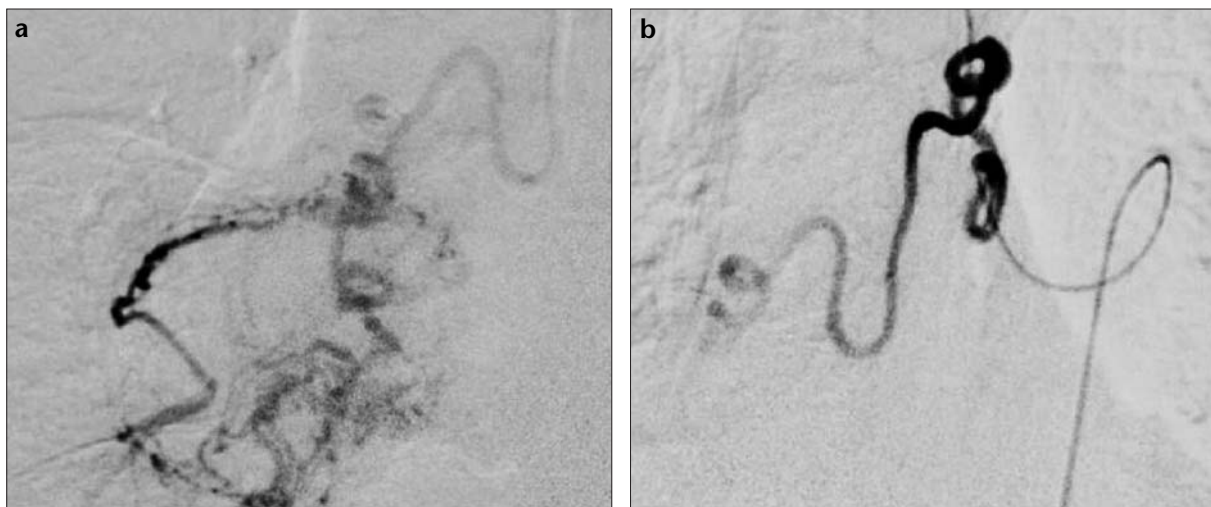


Figure 1. a, b. Selective angiograms of the right bronchial artery of a 58-year-old male patient with massive hemoptysis pre- (a) and post- (b) embolization of bronchiectasis and chronic inflammation.

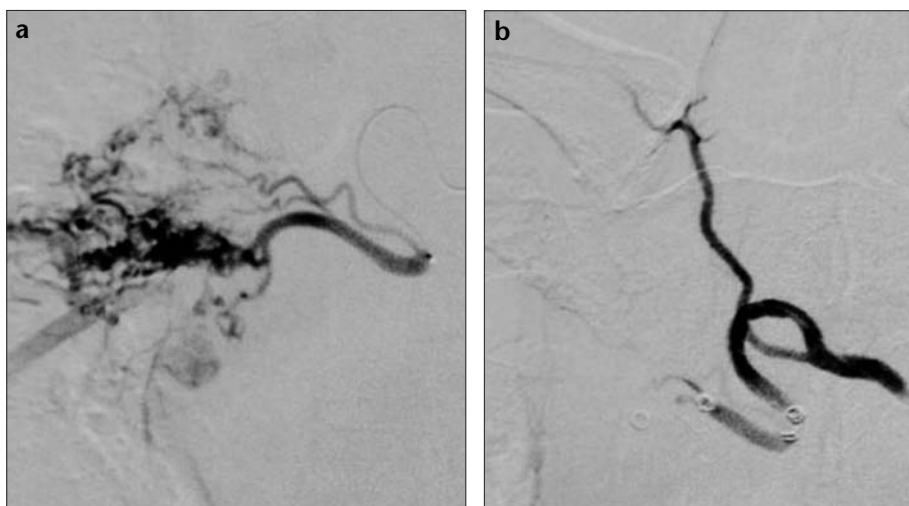


Figure 2. a, b. Right selective bronchial angiograms of a 62-year-old male patient with a history of lower right lobectomy secondary to malignancy demonstrate a bronchopulmonary shunt (a) and coil embolization of the shunt (b) performed with the same diagnostic catheter.

were used for BAE in 7 cases. In 3 cases, BAE was performed with microcatheters (FasTracker 10 or 18 Target Therapeutics, Fremont, CA) using C2 catheters as guiding catheters. Particles >250 microns (PVA, Ivalon, International Therapeutics Corporation Fremont, CA, USA and Embosphere®, Biosphere Medical Malborough, MA, USA) were used in 8 of the BAE patients and mechanical coils (Cook, Bjaeverskov, Denmark) were used in the other two. Embosphere microsphere particles were used for second session embolization of the recurrent hemoptyses of the two patients that had been treated with mechanical coils. Patients were hospitalized for a mean of 3 days (range, 12 hours-17 days) for observation and supplementary treatment until they were hemodynamically and

clinically stable. Siemens (T.O.P., Multistar 2000, Germany) DSA machine was used for all examinations.

Results

In patients whose angiography was negative for hemoptysis, bronchial or non-bronchial systemic arteries demonstrated normal vascular branching and parenchymal enhancement. Contrast medium extravasation, bronchopulmonary shunts, pooling of contrast medium in the parenchyma, and late venous drainage were demonstrated in the other cases. Hemoptyses were controlled during the first endovascular treatment session in all cases (Figure 1). Recurrences were observed in two cases embolized with only mechanical coils on the 20th and

28th post-procedural days due to coil recanalization (Figure 2). Hemoptyses were again controlled with microparticle embolization using Embosphere® microspheres and no recurrence was observed in the 18th and 14th month follow-ups (Figure 3). No complications have developed in any of the cases as a result of the interventions. Embolization was performed in one lung in nine cases and in both lungs in one case. Tuberculosis was the etiological factor in the case of bilateral embolization. Etiological factors of the other nine patients were tuberculosis ($n=2$), sarcoidosis ($n=3$), bronchiectasis ($n=2$), and malignancy ($n=2$). Patients were followed-up for a mean of 8 months (range, 1-21 months).

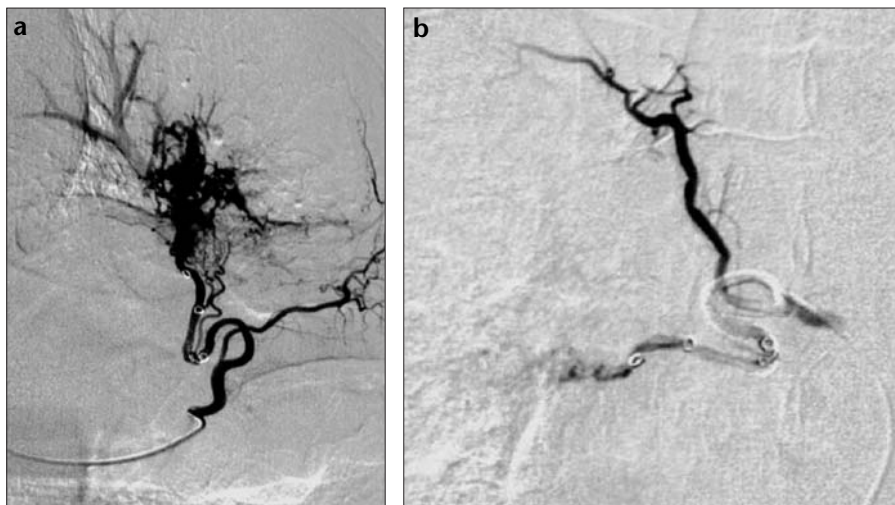


Figure 3. a. Angiogram of the same patient in Figure 2, with recurrence, demonstrates coil recanalization and bronchopulmonary shunt. b. A selective control angiogram following particle embolization with Embosphere® microspheres.

Discussion

Bronchial artery embolization has become a widely accepted endovascular intervention in the treatment and preoperative preparation of massive hemoptysis since it was first reported in 1973 (5-7, 9, 10). Most massive hemoptysis patients are not good candidates for surgery because of weakened pulmonary capacity and other accompanying medical problems (3, 4). The mortality rate is unpredictably high in conservatively managed hemoptysis patients, ranging between 50% and 100% (3). Asphyxia secondary to hemoptysis is the most important factor affecting this rate (4). The mortality rate for the surgical intervention of massive hemoptysis is between 7.1% and 40%, and the rate approaches the upper level when surgery is planned in emergency conditions (1). For these reasons, BAE with endovascular approach appears to be a good choice in patients with massive hemoptysis.

Diagnostic interventions performed in order to detect the cause and location of bleeding are important for the planning and success of the treatment. If the location of the bleeding can be detected in patients with negative angiography who are clinically unstable, or when hemoptysis cannot be controlled with diagnostic procedures, the bronchial artery of the relevant area might be embolized. However, to the best of our knowledge, no studies about the results of patients with negative angiography in whom the location of bleeding was detected and embolized have been reported in the literature.

Chest radiography, CT, and bronchoscopy are the most common modalities that are used for the detection of hemoptysis localization (10). CT and bronchoscopy both have advantages and disadvantages in diagnostic investigation, however, the best results may be achieved with a combination of these two modalities (11). The most important advantage of bronchoscopy is that it also can be a treatment option (11). Two patients in this study received bronchoscopy without CT evaluation, as they were hemodynamically unstable. The DSA and bronchoscopy units were simultaneously notified about the patients. Bleeding control and localization was not possible as the lung airspaces were filled with blood as a result of massive hemoptysis. The patients were intubated before being admitted to the DSA unit. Etiological studies detected tuberculosis in one patient and sarcoidosis in the other patient, but comparative evaluation of the results was not performed, as significant statistical results could not be achieved with the limited number of cases.

There are no pathognomonic DSA findings specific to the etiology of hemoptysis. Common DSA findings like contrast medium extravasation, bronchopulmonary shunt development, increased parenchymal enhancement (hypervascularity), early parenchymal enhancement and late venous drainage, and dilatation and interruption of the bronchial artery may be detected (12).

Bronchial arterial anatomy has been reported in detail in the literature (6,

8-11). Bronchial arteries are not the only vascular structures that cause hemoptysis. Non-bronchial systemic vessels and the pulmonary artery itself might cause hemoptysis (10). There are reports in the literature emphasizing the importance of a nonselective thoracogram in detecting hemoptysis (10). In the present study, nonselective thoracic aortograms detected that hemoptysis was caused by vascular structure in only four cases. The absence of hemoptysis is a result of non-bronchial systemic vessels or pulmonary arteries, but we think selective studies should be performed because of the other 6 cases in hemoptysis evaluation.

Recurrences were observed in the 2 patients that were embolized with mechanical coils in this study. The main purpose of mechanical coil embolization in these patients was to control the hemoptysis preoperatively and to perform surgical interventions afterwards. One of these patients refused subsequent surgical intervention and the other patient was thought to be too high risk for surgery by the surgical team and follow-up was recommended. After our experience with these two patients, microparticles were chosen for embolization in all BAE cases.

Abnormal bronchopulmonary shunts develop in chronically inflamed lung parenchyma and an increase of flow and pressure develops in the inflammatory tissue as a result of this. When fragility of the vessel coincides with this pathologic organization, vessel rupture (hemoptysis) occurs (4). The main purpose of BAE is to selectively embolize this inflamed lung area. Proximal embolization predisposes rapid distal collateral development and also inhibits the chance of reaching the embolization area in need of a second intervention. Large embolizing agents are not preferred for this reason. Conversely, passing of embolizing agents through bronchopulmonary shunts may result in ischemia and necrosis in the lung parenchyma. Particles <250 microns should not be used for this reason (6, 9). Therefore, particular embolizing agents of 250-550 microns were used in this study. PVA has disadvantages, which include recanalization, non-homogenous diameters, and obstruction of the catheters, especially if microcatheters are used. For this reason, Embosphere® microspheres were chosen as the embolizing agent for pa-

tients in whom microcatheters would be used.

Some complications associated with BAE have been reported in the literature. The most common reported complication is chest pain, which has been reported to occur in 24-91% of cases (8, 10). Dysphagia, subintimal dissection of the aorta, mistargeted embolization, transient cortical blindness, and pulmonary infarcts are rare complications (9, 10). The most fearful complication of BAE is ischemia of the spinal cord secondary to spinal arterial occlusion (10). Spinal and bronchial arteries were not originating from the same truncus in any of the angiograms of our patients. However, as Poyanlı et al. previously reported, origination of the spinal and bronchial arteries from the same truncus is not a contraindication for BAE (9). Particles >250 microns are large enough to not occlude spinal arteries distally (5). None of the patients in the present study had any of the complications reported in the literature and mentioned above. This may be due to the limited number of patients in the study.

To the best of our knowledge, no studies comparing the cost of BAE to

surgery have as yet been reported in the literature. In this study, the mean cost to patients in whom microcatheters were not used for embolization was about \$580, including contrast medium. If we also consider that the patients were discharged from the hospital in a mean of 3 days, BAE also appears to be an economical approach.

In conclusion, more reliable and precise data may be obtained as the number of patients increase in this prospective study. However, it is possible to declare, based on the existing data, that BAE is an effective, safe, and economically efficient method for managing massive hemoptysis.

References

1. Fernando HC, Stein M, Benfield JR, Link DP. Role of bronchial artery embolization in the management of hemoptysis. *Arch Surg* 1998; 133:862-866.
2. Haponik EF, Fein A, Chin R. Managing life-threatening hemoptysis: has anything really changed? *Chest* 2000; 118:1431-1435.
3. Najarian KE, Morris CS. Arterial embolization in the chest. *J Thorac Imaging* 1998; 13:93-104.
4. Marshall TJ, Jackson JE. Vascular intervention in the thorax: bronchial artery embolization for hemoptysis. *Eur Radiol* 1997; 7:1221-1227.
5. Remy J, Voisin C, Ribet M, et al. Treatment by embolization, of severe or repeated hemoptysis associated with systemic hypervascularization. *Nouv Presse Med* 1973; 2:2060-2068.
6. Uflacker R, Kaemmer A, Neves C, Picon PD. Management of massive hemoptysis by bronchial artery embolization. *Radiology* 1983; 146:627-634.
7. Hayakawa K, Tanak F, Torizuka T, et al. Bronchial artery embolization for hemoptysis: immediate and long-term results. *Cardiovasc Intervent Radiol* 1992;15:154-159.
8. Mal H, Rullon I, Mellot F, et al. Immediate and long-term results of bronchial artery embolization for life-threatening hemoptysis. *Chest* 1999; 115:996-1001.
9. Poyanlı A, Sencer S, Rozanes İ, Acunaş B. Masif hemoptizinin palyatif tedavisinde etkin bir seçenek: endovasküler girişim. *Toraks Dergisi*; 2001; 2:22-26.
10. Yoon W, Kim JA, Kim YH, Chung TW, Kong HK. Bronchial and nonbronchial systemic artery embolization for life-threatening hemoptysis: a comprehensive review. *Radiographics* 2002; 22:1395-1409.
11. Abal AT, Nair PC, Cherian J. Haemoptysis: aetiology, evaluation, and out-come-a prospective study in a third-world country. *Respir Med* 2001; 95:548-552.
12. Swanson KL, Johnson CM, Prakash UBS, et al. Bronchial artery embolization: experience with 54 patients. *Chest* 2002; 121:789-795.